

## CASE REPORT

### NEAR MISS: A CASE OF RUPTURED RUDIMENTARY HORN PREGNANCY MANAGED AT A TERTIARY CENTRE IN GHANA

Anane-Fenin BAO<sup>1</sup>, Ken-Amoah S<sup>2</sup>; Agbeno EK<sup>2</sup>

<sup>1</sup>Cape Coast Teaching Hospital; Cape Coast

<sup>2</sup>School of Medical Sciences, University of Cape Coast; Cape Coast

#### Abstract

**Objective:** To increase awareness on the potentially life-threatening consequence of rudimentary horn pregnancies, and to reiterate the need for elaborate obstetrics and gynaecologic ultrasound scans to enable early diagnosis. This is the second reported case of this condition in Ghana, and the first in our hospital in its 20 years of existence.

**Case Report and Interventions:** A 26-year old with two previous uneventful pregnancies and vaginal deliveries presented at 33 weeks with a classical clinical picture of haemoperitoneum secondary to a spontaneous uterine rupture and a class IV haemorrhagic shock. Her antenatal records were nil of significance for risk factors for spontaneous preterm uterine rupture. She was resuscitated and had a successful laparotomy which

revealed a unicornuate uterus with a ruptured non-communicating rudimentary horn pregnancy. She recovered remarkably post-operatively. Though she delayed in reporting her symptoms, the prompt management with adherence to referral protocols was life-saving.

**Conclusion:** The diagnosis of rudimentary horns can be quite challenging, but the consequences of a missed diagnosis can be life-threatening. Clinicians and sonographers need to consciously look for such anomalies in their routine gynaecologic and obstetric ultrasound scans. There must also be a high index of suspicion for a ruptured rudimentary horn in a spontaneous pre-term rupture of an unscarred uterus.

**Key Words:** Rudimentary horn, post-rupture, haemoperitoneum

#### Introduction

Unicornuate uterus forms 2.5-13.2% of uterine malformations<sup>1</sup>. It is a Class IIb under the Buttram and Gibbons classification of 1979,<sup>2</sup> and a V0C0U4aA0M0 under the VCUAM classification developed by Oppelt et al in 2005<sup>3</sup>. A rudimentary horn may exist in a unicornuate uterus due to incomplete development of one mullerian duct associated with the partial fusion of the contralateral one. It accounts for 74% of all unicornuate uteri. This rudimentary horn may or may not be communicating with the endometrial cavity of the unicornuate uterus. 70–90%, however, are noncommunicating<sup>4</sup>. The horn may or may not have an endometrium and when it does, there may be haematometra. Endometrial tissue can also escape into the peritoneal cavity through the tubes and hence cause endometriosis. Haematometra and endometriosis can therefore cause chronic pelvic pain<sup>5</sup>. A common association of unicornuate uterus is renal malformation, which is seen in 36% of cases. In view of this, it is important to investigate such women for these anomalies<sup>6</sup>.

Pregnancy in a non-communicating rudimentary horn is uncommon. It occurs in 1 in 76,000 pregnancies and they usually terminate by rupture in 50% of cases<sup>4</sup>. The pregnancy occurs through the transperitoneal transfer of the spermatozoon or the fertilized ovum and they are associated with poor reproductive outcomes because of increased abortion rate and low fetal survival rate. In isolated cases, a live infant may be delivered, but 70-90% of the cases terminate in rupture before the 20th week. The rupture of a rudimentary horn pregnancy can occur between the 5<sup>th</sup> and the 35<sup>th</sup> week, depending on the thickness of the myometrium of the horn and its ability to hypertrophy and dilate<sup>6</sup>. Mauriceau<sup>7</sup> reported the first case of a ruptured rudimentary horn in 1669<sup>6,7</sup>. Several others have subsequently reported rudimentary horn pregnancies, but until 2008 when Buntugu et al.<sup>8</sup> published one in Ghana, there was no such report from West Africa, and none has been reported after.

Diagnosing a rudimentary horn pregnancy can be very challenging even with the advancement of diagnostic imaging. It is even more difficult to suspect in a woman with prior vaginal delivery. Rudimentary horn pregnancies are usually detected after rupture. Advanced sonography and magnetic resonance imaging (MRI) have made pre-rupture diagnosis possible in several instances. Tsafirir et al.<sup>9</sup> derived three sonographic criteria for the diagnosis of a rudimentary horn. These are: an asymmetric bicornuate uterus pattern; no continuity between cervical canal and the

**Corresponding Author: Dr. Betty Akua Oparebea**

**Anane-Fenin** Cape Coast Teaching Hospital

P. O. Box CT 1363

Tel: +233209886563

Email Address: [oparebea81@gmail.com](mailto:oparebea81@gmail.com)

Conflict of Interest: None Declared

lumen of the pregnant horn; and the presence of myometrial tissue around the gestational sac. It however requires expertise and a high index of suspicion<sup>4,6,9</sup>.

### Case report:

A 26-year-old Ms FT, G3P2AA, both by spontaneous vaginal delivery, with a 33-week pregnancy, reported to the hospital in an ambulance. A call had been placed by the referral hospital to our facility two hours prior to her arrival. The referral diagnosis was intrauterine foetal demise and severe anaemia.

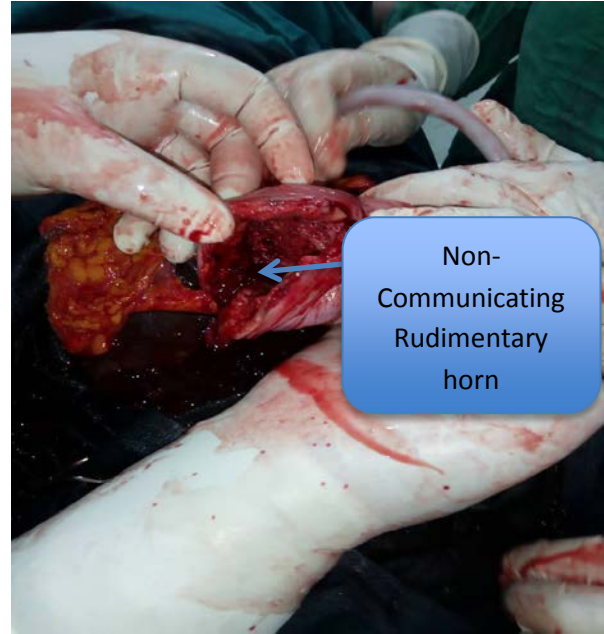The patient began experiencing generalized persistent abdominal pain five days prior to presentation. The pain was gradual in onset, but increased in intensity over the days. It was associated with easy fatigability and dizziness. She however did not report it until the day she was rushed to the Health Centre that offers her routine antenatal care. She was transferred to the referral hospital and brought to our facility on the same day.

The patient's two previous pregnancies and vaginal deliveries were uneventful. In this index pregnancy, she had had three antenatal visits at the rural health centre and had done one 2-dimensional obstetric ultrasound scan at 16 weeks, which showed a normal intrauterine gestation.

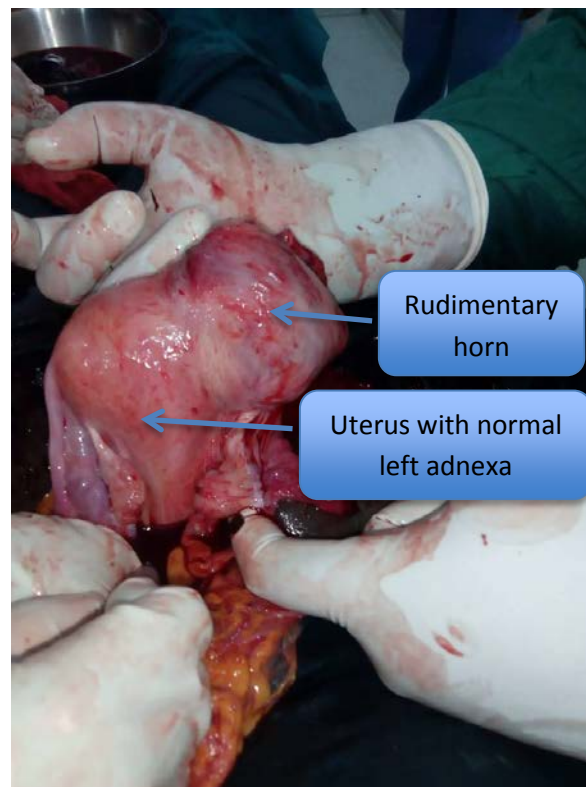
She arrived in an ambulance with intranasal oxygen and a unit of blood in-situ. Earlier, she received two units of blood at the referral centre. The facility duly informed our unit about the patient's state, the interventions carried out and their limitations with respect to further management. The patient was in class IV haemorrhagic shock on arrival: blood pressure was 60/40mmHg; pulse - 129 beats per minute, weak volume and thready; respiratory rate was 32 cycles per minute; oxygen saturation was 84% on intranasal oxygen. A full blood count at our facility revealed a haemoglobin level of 2.1g/dl. Foetal heart beat was absent on auscultation.

A quick examination and abdomen-pelvic ultrasound scan revealed haemoperitoneum and foetal demise. An exploratory laparotomy was performed immediately under general anaesthesia and the intraoperative findings were: haemoperitoneum of about 2 litres; ruptured right non-communicating rudimentary horn; macerated 2.0kg male baby extruded into the peritoneal cavity; a partially-separated placenta in the rudimentary horn. The right ovary and the contralateral tube were normal. Exploration of the pelvis revealed no pelvic kidney. The rudimentary horn was excised, and the uterus repaired. An ipsilateral salpingectomy was also performed. Two units of whole blood were transfused intra-operatively and three more after surgery. Immediate post-operative condition was satisfactory and her recovery from the surgery - remarkable. She was discharged on day seven after surgery in a stable state. An abdominopelvic ultrasound scan done before discharge showed no gross renal anomalies. In order to rule out an ectopic ureter,

duplication of the renal pelvis and a medullary sponge kidney, an intravenous urogram (IVU) was requested, but this could not be done at that time due to financial challenges on the part of the patient. She was to be reviewed a week later at the outpatients' department with the IVU report, but was lost to follow-up.



**Fig 1:** Ruptured Rudimentary Horn



**Fig 2:** Posterior view

## Discussion

The pregnancy occurred in a horn that was not communicating with the uterine cavity. It could either have occurred as a result of a transperitoneal transfer of spermatozoon, which then fertilized an ovum released by the right ovary or a migration of the fertilized ovum from the uterine side to the rudimentary horn through the right tube.

In the case of Ms FT, the uterine anomaly was not diagnosed with her 16-week ultrasound scan. This could be due to the fact that the condition is rare, and hence not actively looked for on routine obstetric scans. It may also be due to minimal expertise or experience of the sonographer and the possible lack of sophisticated ultrasound machines in that rural area. If it had been suspected earlier, more advanced imaging techniques could have been employed and this near-miss averted.

Again, the rupture occurred neither in the first nor the second trimesters as is often reported, but in the third trimester (33 weeks). This buttresses the point that some rudimentary horns with thick musculature can contain a pregnancy to a later gestational age, making the diagnosis more unsuspecting, and the consequences dire. It is therefore important to emphasize the application of the three diagnostic sonographic criteria mentioned earlier in all obstetric and gynaecologic scans.

In this case report, the interventions were swift and timely, both at the referral and receiving centres. The pre-referral telephone call was an important contributory factor to averting this near-miss, as it enabled us to prepare adequately to receive and manage the patient.

## Conclusion

This case report highlights the maternal/ foetal mortalities and near-misses associated with rudimentary horn pregnancies. It is clear that although obstetric ultrasonography has become more available to us than previously, rudimentary horn pregnancies can still elude us. A high index of suspicion and adequate expertise are therefore required for pre-rupture diagnosis. This case also prompts us to suspect a congenital uterine anomaly in a preterm unprovoked rupture of an unscarred uterus. An effective referral (where necessary) and swift and timely interventions are the keys to successful management of a ruptured rudimentary horn.

## Recommendations

In view of the above, we recommend that sonographers be adequately trained to apply the three diagnostic sonographic criteria for the detection of rudimentary horn pregnancies. We should also hasten steps to regulate the seemingly booming business of ultrasound in the country.

Finally, we recommend that, as standard protocol demands, pre-referral telephone calls should be strictly adhered to. All hospitals must make their telephone numbers available and accessible to peripheral centres for easy communication and joint management of emergencies.

## References

1. Donderwinkel PFJ, Dijrr JPI, Willemsen WNP. The Unicornuate Uterus: Clinical Implications. *Eur J Obstet Gynecol and Reprod Biol.* 1992;47:135-139
2. Buttram VC, Gibbons WE. Mullerian Anomalies: A Proposed Classification (An Analysis of 144 Cases). *Fertil Steril.* 1979; 32:40-46.
3. Oppelt P, Renner SP, Brucker S, et al. The VCUAM (Vagina Cervix Uterus Adnex-associated Malformation) Classification: a new classification for genital malformations. *Fertil Steril.* 2005; 84:1493-1497.
4. Lai Y-J, Lin C-H, Hou W-C, Hwang K-S, Yu M-H, Su H-Y. Pregnancy in a noncommunicating rudimentary horn of a unicornuate uterus: Prerupture diagnosis and management. *Taiwan J Obstet Gynecol.* 2016; 55: 604-606.
5. Hillman RT, Chin HG, Mody SK. Management of Second Trimester Fetal Demise in a Noncommunicating Uterine Horn. *Case Rep Obstet Gynecol.* 2015; 2015: 927037.
6. Kanagal D V., Hanumanalu LC. Ruptured Rudimentary Horn Pregnancy at 25 Weeks with Previous Vaginal Delivery: A Case Report. *Case Rep Obstet Gynecol.* 2012; 2012:1-4.
7. F. M. Traite Des Maladies Des Femmes Grosses et de celles qui sont accouchées.. 1721; 1.
8. Buntugu K, Ntumu M, Ameh E, Obed S. Rudimentary horn pregnancy: pre-rupture diagnosis and management. *Ghana Med J.* 2008; 42:92-94.
9. Tsafirir A, Rojansky N, Sela HY, Gomori JM, Nadjari M. Rudimentary Horn Pregnancy. *J Ultrasound Med.* 2005; 24:219-223.