

MODIFIED OPEN OMENTAL PLUGGING OF PEPTIC ULCER PERFORATION IN A MUNICIPAL HOSPITAL IN GHANA

Wegdam H H J & Hillah A A

Department of Surgery, Holy Family Hospital, Techiman, Brong Ahafo, Ghana.

Abstract

Background: This prospective study conducted in the Holy Family Municipal Hospital in Techiman Ghana, aimed at providing data on gastric and duodenal perforations in a municipal hospital in a developing tropical country and to report and evaluate the outcome of surgery with regard to the use of a modified open omental plugging in our setting.

Patients and Interventions: Between July 2004 and October 2008, 56 patients were recorded: 45 patients had gastric and 11 patients duodenal perforation. (Gastric/Duodenal perforation ratio: 4.0:1). All patients

received the same treatment with a modified technique of over-suturing the perforation with use of a “champagne cork” omental plug. The procedure of this plugging is described. Total mortality in the study was 6 (10.7 %), all in the gastric, none in duodenal perforations.

Conclusion: We conclude that the use of open “champagne cork” omental plugging is a reliable method of closure of perforations in peptic ulcer disease in our setting and contributed to an improvement of our mortality rate.

Keywords: Open omental plugging, champagne cork, peptic ulcer, perforation

Introduction

In 2004 a retrospective study of 31 patients with perforated peptic ulcers was done in our hospital as part of our clinical audit. Period of review was Jan. 2002 to May 2004. Of these, there were 21 cases of gastric perforation (67.7%) and 10 cases of duodenal perforation (32.3%). Mortality was 16% (GP 60% and DP 40%). The operative procedures were very variable. Some were simple closure with one or two layers, with or without an omental patch¹.

To improve our post-operative outcome it was decided to adopt one single operative procedure, namely: “champagne cork omental plugging”. After designing a protocol form to be filled pre-, intra- and post-operatively, we started a prospective study. Our objectives were to provide a data on gastric and duodenal ulcer perforations in our tropical setting and also to evaluate the outcome of surgery with regard to closing peptic ulcer (PU) perforation by omental plugging.

Patients and methods

Fifty-six consecutive patients in Holy Family Hospital Techiman were included in the study from July 2004 to October 2008. Further data recorded were as

follows: patient’s demography, onset of acute signs, arrival at hospital, co-morbidity/risk factors, X-Ray investigations. These were in addition to operative findings and post-operative treatment and complications and date of discharge. After an initial resuscitation the patients underwent an emergency operation. All patients included have been diagnosed as peptic ulcer with perforation, clinically and at laparotomy. At laparotomy, in case of gastric perforation a biopsy of the edge of the perforation was taken for histopathology. Closure of the perforation was done by the procedure we have called “*Champagne cork omental plugging*” (Figure 1). Abdominal lavage was done and a drain was inserted close to the area of perforation. Postoperatively, intravenous antibiotics and ranitidine or omeprazole were administered for 14 days. *Helicobacter pylori* eradication treatment was given postoperatively to all patients.

Champagne cork omental plugging procedure

The following are steps involved in the “Champagne cork omental plugging” technique employed in this series.

1. No attempt is made to excise the ulcer.
2. In case of gastric perforation a biopsy of the edge of perforation is taken for histopathology (Figure 2).
3. A total of 3 or 4 seromuscular sutures of vicryl 1 are placed onto the normal healthy tissue of stomach or duodenum on either side of the perforation (plugging 1) (Figure 3).
4. A vascularised strand of omentum is placed directly under the sutures onto the perforation (plugging

Author for Correspondence:

Dr.H.H.J.Wegdam

Kazernelaan 19,

6711 RK Ede,

Holland

E mail: wegdam@tiscali.nl

Conflict of interest: None declared

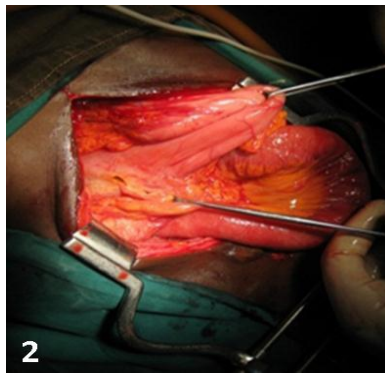


Figure 1: Like the fixation of a Champagne cork

Figure 2: Perforation site

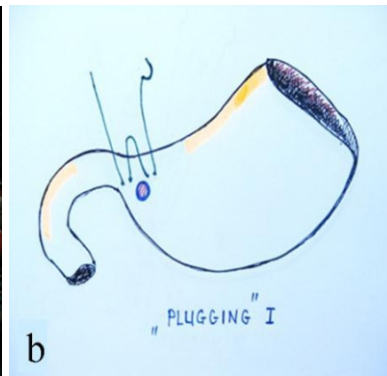
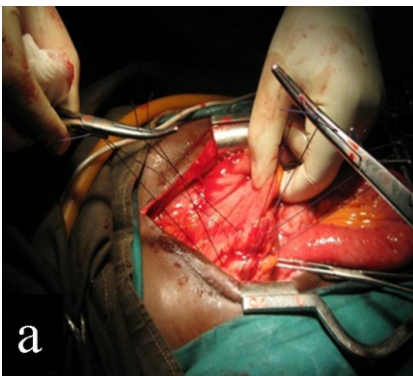

Figure 3: Sutures placed (Plugging I)
a: Operative procedure. **b:** Diagrammatic explanation of procedure.

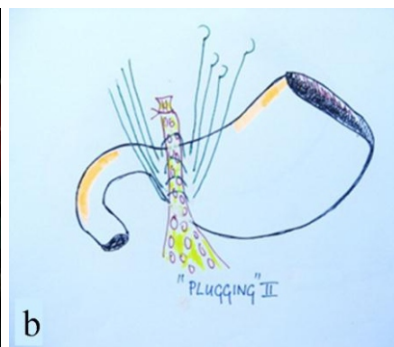
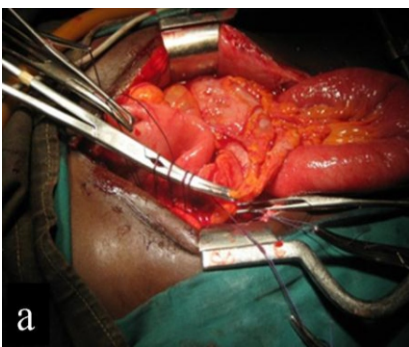


Figure 4: Lifting sutures and pulling slip under (Plugging II)
a: Operative procedure. **b:** Diagrammatic explanation of procedure.

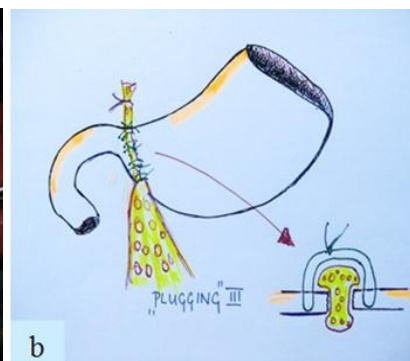
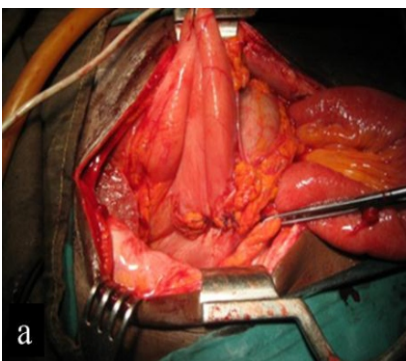


Figure 5: Perforation closed with omental plug (Plugging III)
a: Operative procedure. **b:** Diagrammatic explanation of procedure.

2) (Figure 4) and the sutures are knotted above it without tension (plugging 3) (Figure 5). No omentum is put inside the suture in contrary with other advocated plugging procedures,^{2,3,4} in order to insure free circulation in the strand.

- No attempt was made to close the perforation prior to plugging of the omentum into the perforation.

Results

Between July 2004 and October 2008, 56 patients were treated using the procedure outlined above. There were 50 males (89.3%) and 6 females (10.7%). The age distribution is shown in Figure 6 and ranged between a minimum of 20 years and a maximum of 100 years (median 42 years and IQR 35-50 years) (Figure 6). Gender distribution is also shown in Figure 6. Age of patients and site distribution of the perforations are shown in Figure 7.

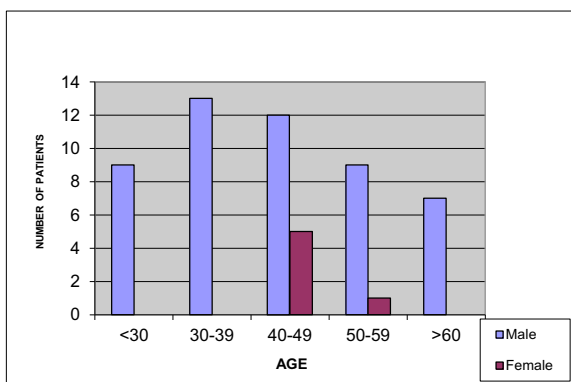


Figure 6: Age/gender distribution

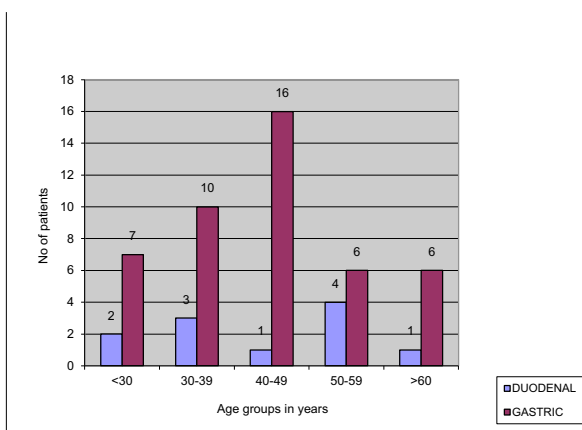


Figure 7: Age/site of perforation distribution

Chest X-rays showed free air under the diaphragm in 54 patients (96.4%), but were normal in 2 cases (3.6%). The operative procedures were performed by the following categories of doctors: In 7% of the cases they were treated by a Surgical Consultant (experienced Fellow in Surgery), 46% by Surgical Residents (Medical Officers in training for Membership Surgeon) and 47% by Medical Officers (Qualified and Regis-

tered Doctor doing independently several surgical operations in our setting) or House Officers (Qualified Doctor before final Registration as a Medical Officer, working under strict supervision in our setting). The procedures lasted a minimum of 30 minutes and a maximum of 130 minutes (mean, 70 minutes). The perforations varied in size and 3.6 % were smaller than 3 mm. diameter, 91.1% were between 3 and 10 mm. diameter and 5.4% were larger than 10 mm. diameter. Forty-five patients had gastric and 11 duodenal perforation (ratio = 4.0:1).

Duration of acute signs before presentation

Data were only available for 47 patients. Of these, 14 (30%) presented within 24 hours after first acute signs, 5 (10%) in the second 24 hours, 14 (30%) after 3 days, 13 (28%) between 4 and 7 days and one (2%) after one week (Figure 8).

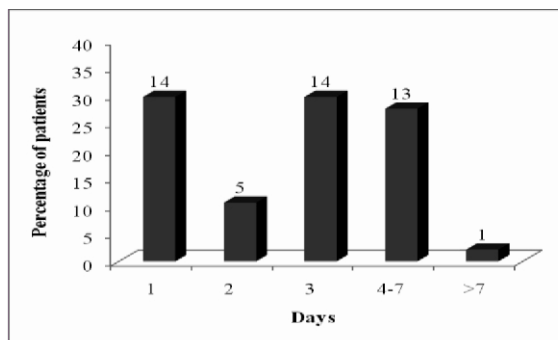


Figure 8: Duration of acute signs before presentation

Seven cases (12.5%) had post-operative complications. Three cases had surgical site infection, 2 had persistent hiccups, 1 case of intra-abdominal abscess and 1 leakage of repair.

Overall mortality in the study was 6 (10.7%), all in the gastric and none in the duodenal perforations. One of the 6 was a female, 5 were males. Three patients died within 24 hours.

The other 3 died on the 2nd, 4th and the 11th post-operative day respectively. Causes of death were: septic shock in 4 patients, pulmonary embolism in 1 patient and leakage with sepsis in one patient. Duration of hospital stay for the patients ranged between a minimum of 6 days and a maximum of 36 days (average 11 days). Of the biopsies submitted, only two results were received. Both were benign.

Discussion

In our series gastric perforations out-numbered duodenal ones by a ratio of 4:1. The condition affects more males than females with a ratio of 8.3:1, (comparable with what Ohene-Yeboah found in Kumasi, Ghana, 2.8:1 and 2.4:1 respectively in a prospective study of 331 cases of PU perforations. The overall mortality in their series was 22.1 %) ⁵.

More than 50% of our cases were between 35 and 50 years. There was serious delay in presentation to hospital: only 14 patients came within 24 hours and 33 came later, even 14 of them after 3 days of onset of acute symptoms.

Routine chest X-Ray showed free air under the diaphragm in 96.4% of our cases. Most (91.1%) of our patients had perforation sizes ranging between 3 and 10 mm. diameter. Our series recorded 1 patient (1.9%) with leakage from the plugged perforation after operation out of 56 patients. Wound infection is the most frequent post-operative complication representing 5.3 % of the cases.

The overall mortality rate in our series is 10.7 % and in the group of gastric perforation only. No death was recorded as a result of operation of duodenal perforation. Half of the patients died within 24 hours after operation. Septic shock was the most important cause of death. Biopsies were always taken, but patient were often not interested to go and pay extra for the results in an outside hospital facility.

In the literature we find a wide range of mortality rates in emergency operations for PU-perforation (6-30%)⁶. The mortality rate of 10.7 % in our group of 56 patients seems better than that reported from Kumasi⁵, but their number of patients was much higher (331). Our mortality rate is difficult to compare with other studies, because of various methods of handling the perforation, differences in time intervals between onset of symptoms and surgical intervention, and also different patient populations. For example in presentations during the Baltasar Gerard Symposium Delft Holland⁷ on operative management of PU perforation in three Dutch hospitals of different sizes, the median ages of the patients were much higher (62-68yrs compared to 42 years in our series). The delay in their series is much shorter, but their mortality rates after operation is much higher (17-29%). The reason for their higher mortality rate could be due to the many accompanying diseases in the elderly Dutch patient groups.

Conclusion

We consider open champagne cork omental plugging in our setting by doctors with different levels of experience a reliable method of closure of a peptic ulcer perforation, with only one leakage and an acceptable mortality rate. With the implementation of this type of omental plugging as a routine treatment for this condition we have improved on our mortality rate (10.7% versus a previous study of 16.1%) and on our complication-rate (12.5 versus 19% formerly).

Acknowledgements

We wish to thank Dr. Juventus Ziem for analysing our data. We also thank Dr. Noel Tolgou and Dr. Clemens Ativor for their support.

References

1. Jennikens A, Wissink K. Retrospective study on Mortality after Gastric and Duodenal Perforations in Holy Family Hospital Techiman Ghana (internal pilot study of Nijmeegs Institute of International Health (NIIH) Radboud University Nijmegen Holland).
2. Cellan-Jones CJ. A rapid method of treatment in perforated duodenal ulcer. *BMJ* 1929; 1076-1077.
3. Graham RR; The treatment of perforated duodenal ulcers. *Surg Gynecol Obstet* 1937; 235-238.
4. Bertleff MJOE, Lange JF. Perforated Peptic Ulcer Disease: a review of history and treatment. *Digestive Surgery* 2010 Vol 27 No3.
5. Ohene-Yeboah M, Togbe B. Perforated gastric and duodenal ulcers in an urban African population. *West Afr J Med* 2006; 25: 205-211.
6. Svanes C, Lie RT, Svanes K, Lie SA, Søreide O. Adverse effects of delayed treatment for perforated peptic ulcer. *Ann Surg* 1994; 220(2):168-175.
7. Symposium Gecomplieerd Ulcus Lijden. Complicated Ulcer Disease. 2006. Delft Baltasar Gerards Foundation.