

CASE REPORT

BRACHIAL ARTERY PSEUDO-ANEURYSM IN A TODDLER DUE TO PENETRATING TRAUMA

Gyedu A^{1,2} & Agbedinu K²

¹Department of Surgery, School of Medical Sciences, Kwame Nkrumah University of Science & Technology, Kumasi, Ghana, ²Directorate of Surgery, Komfo Anokye Teaching Hospital, Kumasi, Ghana

Summary

Objective: We present a toddler who developed a pseudo-aneurysm of the left brachial artery one month after sustaining a cut on his left forearm.

Case Report and Interventions: A one and a half year-old boy was referred with a swollen and painful left forearm which was bleeding from a focal point. He was being managed as a case of venous hematoma and was referred when the bleeding could not be controlled. A clinical diagnosis of pseudo-aneurysm was confirmed by Doppler ultrasonography and repair done with a di-

rect closure of the arterial defect. **Conclusion:** Although brachial artery pseudoaneurysms (BAPs) following penetrating trauma are most likely to be iatrogenic, they can also occur outside the clinical setting and should not be mistaken for a venous hematoma. Duplex ultrasonography should be used as an initial screening and diagnostic tool to secure an early diagnosis reserving more invasive tests for patients requiring more complex procedures. Management should be surgical.

Key words: brachial artery, pseudo-aneurysm, penetrating trauma, toddler

Introduction

Brachial arterial injuries in infants and toddlers are not uncommon and are usually due to iatrogenic injury following venipuncture. Such injuries can in turn result in the formation of arterio-venous fistulas, acute limb ischemia¹ and very rarely pseudo-aneurysms. Reports of brachial artery pseudo-aneurysms (BAP) in this age group due to penetrating trauma outside the clinical setting are uncommon. We present a toddler whose bleeding pseudo-aneurysm of the left brachial artery was repaired with direct closure of the arterial defect.

Case report and interventions

A 1¹/₂-year-old boy was referred to our clinic with a 3-week history of swollen and painful left forearm which was bleeding from a focal point. The patient was injured by a broken piece of glass about a month earlier which healed with a scar. A mass then developed at the site, which later started bleeding. He was being managed at the referring hospital with haemotransfusion, haematinics and wound dressings.

He had no other bleeding sites and no significant or relevant past medical and family history. On examination, he was mildly pale, anicteric, afebrile with a respiratory rate of 29 cycles/min and a pulse of 114 beats/min that was regular and of good volume. Temperature was 37.9°C.

There was a 5X4cm swelling on the antero-medial aspect of the proximal left forearm with a 1X1cm ulcer at the apex, which contained a thrombus (Fig 1). The swelling was tender, warm to touch but non-pulsatile. Radial and ulnar pulses were palpable.

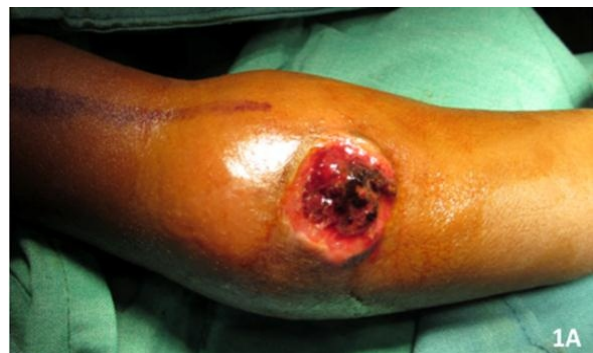

Figure 1: Pseudoaneurysm causing swelling of the left forearm

Mobility of the left upper extremity was normal but his left fingers showed some degree of clawing. Other systemic examination was normal. His haemoglobin was 3.6g/dL, white blood cell count was 20,850/ μ L

Author for Correspondence:

Dr. Adam Gyedu

Department of Surgery, School of Medical Sciences

K.N.U.S.T

Kumasi, Ghana

E mail: drgyedu@gmail.com

Conflict of interest: None declared

and platelet count was $406 \times 10^9/L$. A diagnosis of bleeding pseudo-aneurysm of the proximal left forearm secondary to a cut sustained from a broken piece of glass was made. The patient was resuscitated with IV crystalloids, haemotransfusion and antibiotics. The clinical diagnosis was confirmed by Doppler ultrasonography (Fig. 2).

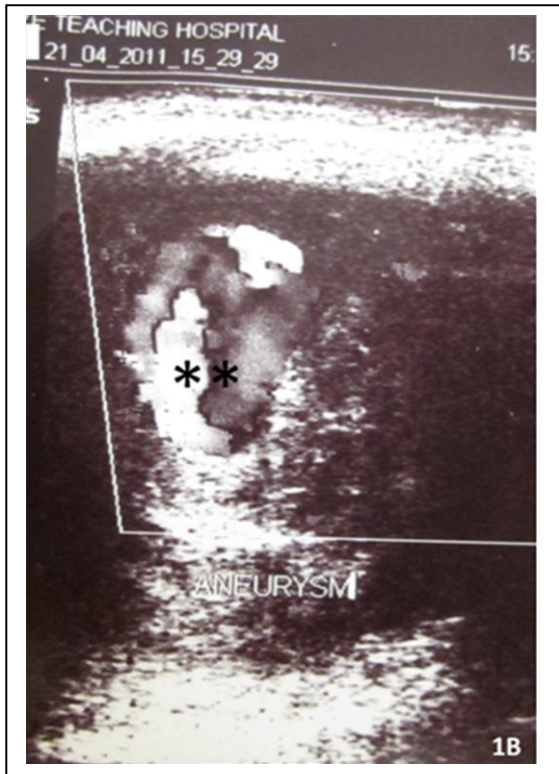


Figure 2: Doppler ultrasound image showing turbulent flow (***) within the pseudoaneurysm

After proximal control of the brachial artery at surgery, the pseudo-aneurysm was opened up and emptied to reveal a 0.2cm defect in the distal brachial artery proximal to its bifurcation (Fig. 3). The defect was closed directly with a single 6/0 polypropylene stitch after which the surgical site was lavaged with antibiotic solution. A vacuum drain was placed at the

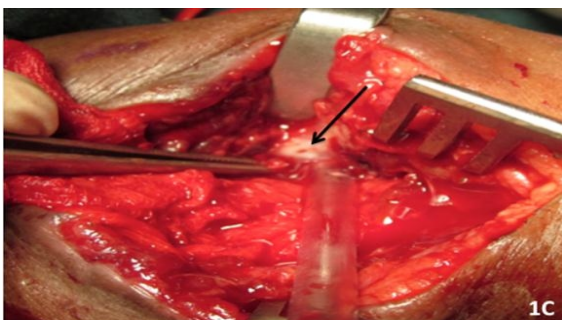


Figure 3: Defect (arrow) in the brachial artery

site and the wound closed primarily in layers. Postoperatively, radial and ulnar pulses were present and palpable.

Postoperative course was uneventful and patient was discharged on postoperative day 5. His clawed fingers resolved with physiotherapy but the patient was lost to long-term follow-up.

Discussion

Paediatric arterial injuries usually result from cardiac catheterization in children with congenital heart disease or from multiple arterial punctures for blood gas determination, bypass cannulation, arterial monitoring catheters, or venipuncture. As a result of such arterial injuries thrombotic occlusion, arterio-venous fistulas, chronic ischemia, and formation of pseudo-aneurysms may occur.^{1,2}

Pseudo-aneurysms result from disruption of vessel wall continuity. This leads to bleeding into the surrounding tissues, but the circulating blood is contained in a cavity surrounded only by adjacent tissues, fascia, and thrombus and not by normal arterial wall components as in true aneurysms.³ Pseudo-aneurysm can take from a few hours or weeks to as long as 18 months after injury, to develop. Usual presenting symptoms are a palpable pulsatile or non-pulsatile expanding mass with palpable distal pulses and a viable extremity. Late complications include rupture, thrombosis with acute or chronic limb ischemia that may manifest as pain and paraesthesia, cold intolerance, distal embolization with digital ischemia, extrinsic compression of nearby neurovascular structures, necrosis of the overlying skin and subcutaneous tissue and growth retardation.^{4,5}

Differential diagnosis includes simple hematomas, tissue oedema, ganglions, synovial cyst, abscess, neural tumour, muscular fibroma, and Raynaud's disease.^{3,6}

The diagnosis of BAP following trauma may be delayed because the aneurysm is mistaken for a venous hematoma. One should therefore observe any hematoma following trauma for growth, pulsatility, and signs of distal ischemia since early diagnosis and intervention may require lesser reconstructive procedures. Our patient had no personal or family history of aneurysm, recent vascular catheterization or infection and had an uneventful birth. The only likely cause of his pseudo-aneurysm was penetrating trauma secondary to the glass cut but was only referred after the suspected 'bleeding hematoma' could not be controlled.

Duplex US scanning provides an excellent screening tool, and in cases of injuries detected early, may be the only diagnostic tool used.⁷ In instances where the cause of the BAP is unclear, a complete check-up of other arteries such as vertebral, radial, renal and iliac arteries is necessary to find another aneurysmal location.

Angio-magnetic resonance imaging (angio-MRI) and CT angiography have also been found to be invaluable in preoperative planning especially in longstanding pseudo-aneurysms that require a more complex reconstructive procedure.⁷

Management of brachial artery aneurysms in paediatric patients is challenging because of the potential risk of ischemic complications including acute thromboembolic events and chronic limb growth disturbance. There is also the technical difficulty with respect to the small diameter of the artery at that age (1–2.5 mm).⁶

Non-operative management strategies that are successful in adults, such as ultrasound-guided compression obliteration⁸ and intracavitary thrombin injection,⁴ are employed less frequently in children because of unfavourable anatomic relations and reported complications.³

Surgical options include aneurysmectomy and repair of the arterial defect, which could be done by simple closure of the defect or direct end-to-end anastomosis. When the arterial defect is too long, interposition of an autologous venous graft may be necessary, using basilic or saphenous veins.

There is some controversy as to whether BAPs can be ligated in the paediatric age group. While some authors^{3,9} believe that simple ligation does not lead to limb loss because of the small muscular mass and good neo-angiogenic potential, others^{6,10} believe that, with very few exceptions, ligation should be contraindicated because of the potential risk of limb loss.

Endovascular treatment is not considered an appropriate therapeutic approach in infants and toddlers because of excessive radiation exposure and also a risk of stent migration as the limb grows.⁶

Post-operative surveillance with physical examination and Duplex ultrasonography is recommended to follow-up on limb growth and graft permeability.

Conclusion

Although BAPs following penetrating trauma are most likely to be iatrogenic, they can also occur outside the clinical setting and should not be mistaken for a venous hematoma. Duplex US should be used as an initial screening and diagnostic tool to secure an early

diagnosis reserving more invasive tests for patients requiring more complex procedures. Management should be surgical.

References

1. Gamba P, Tchaprassian Z, Verlatto F, Verlatto G, Orzali A, Zanon GF. Iatrogenic vascular lesions in extremely low birth weight and low birth weight neonates. *J Vasc Surg.* 1997; 26:643–646
2. Lin PH, Dodson TF, Bush RL, Weiss VJ, Conklin BS, Chen C, Chaikof EL, Lumsden AB. Surgical intervention for complications caused by femoral artery catheterization in pediatric patients. *J Vasc Surg.* 2001; 34:1071–1078.
3. Landau D, Schreiber R, Szendro G, Golcman L. Brachial artery pseudo-aneurysm in a premature infant. *Arch Dis Child Fetal Neonatal Ed.* 2003; 88:F152–F153.
4. La Perna L, Olin JW, Goines D, Childs MB, Ouriel K. Ultrasound-guided thrombin injection for the treatment of post-catheterization pseudo-aneurysms. *Circulation.* 2000; 102:2391–2395.
5. Fann JJ, Wyatt J, Frazier RL. Symptomatic brachial artery aneurysm in a child. *J Pediatr Surg.* 1994; 29:1521–1523.
6. Pages ON, Alicchio F, Keren B, Diallo S, Lefebvre F, Valla JS, Poli-Merol ML. Management of brachial artery aneurysms in infants. *Pediatr Surg Int.* 2008; 24:509–513.
7. Dzepina I, Unusic J, Mijatovic D, Bulic K. Pseudo-aneurysms of the brachial artery following venipuncture in infants. *Pediatr Surg Int.* 2004; 20: 594–597.
8. Hajarizadeh H, LaRosa CR, Cardullo P, Rohrer MJ, Cutler BS. Ultrasound-guided compression of iatrogenic femoral pseudo-aneurysm failure, recurrence, and long-term results. *J Vasc Surg.* 1995; 22:425–430.
9. Sayin AG, Bozkurt AK, Cangel U. A brachial aneurysm in childhood caused by Ehlers–Danlos syndrome. *J Cardiovasc Surg (Torino).* 2001; 42:687–689
10. Duteille F, Costargent A, Perrot P, Pannier M. False aneurysm of a brachial artery in a very premature newborn. *J Reconstr Microsurg.* 2008; 24:147–9.